Original Article

Emerging Technologies in Diabetic Retinopathy Screening, Diagnosis, and Clinical Management

[1]Dr Rehan Moinuddin Shaikh, [2]Kamran Safdar, [3]Dr Khalid Rafique, [4]Dr Asher Mehboob Sheikh, [5]Dr Sidra Manzoor, [6]Dr Kainat Ishaq

[1]Sharif Medical College, Lahore
[2]Service Hospital, Lahore
[3]Assistant professor ophthalmology, Rashid latif medical college, Lahore.
[4]PNS Karachi
[5]Ayub Medical College
[6]Ayub Medical College

Received: January 25, 2026 Accepted: March 02, 2026 Published: July 06, 2026

Abstract

Introduction: Diabetic retinopathy (DR) is one of the international leaders in causes of avoidable blindness due to hyperglycemia-related microvascular damage to the retinal microvasculature. It is asymptomatic and lacks a prodromal, and therefore detection is key. One of the rare but dangerous ones is diabetic macular edema (DME), which may occur at any phase of retinopathy. DME is enhanced vascular permeability with resultant fluid accumulation in the macula the portion of the retina devoted to central vision and is a major cause of visual disability in diabetics.

Objective: The aim of the present article is to present a general overview of the available strategies for screening, diagnosis, and management of diabetic retinopathy with a special focus on evidence-based therapies that alleviate the disease burden and maintain visual function.

Methods: Systematic literature study and study of critical clinical guidelines were undertaken to compare different diagnostic methods and therapeutic modalities, namely laser photocoagulation, intravitreal pharmacotherapy, and surgery.

Results: Detection modalities like dilated fundus examination at intervals, high-resolution fundus imaging, and tele ophthalmology have maximally improved the detection rate at the early stage. Panretinal photocoagulation, anti-VEGF therapy, and vitrectomy have been tremendously successful in avoiding loss of vision at various stages of DR.**Conclusion:** Systematic management by following combined systematic screening, early diagnosis, and stage-wise therapeutic intervention is mandatory in an attempt to decrease the visual as well as socioeconomic load of diabetic retinopathy.

Keywords: Diabetic retinopathy; retinal screening; laser photocoagulation; anti-VEGF treatment; fundus photography; tele ophthalmology; diabetic macular edema; preservation of vision; ophthalmic interventions; disease management.

Introduction

Diabetic retinopathy (DR) is a microvascular complication of diabetes and a leading cause of preventable visual handicap and blindness globally [1]. Approximately one-third of all people with diabetes are estimated to develop any category of DR throughout their life across the globe. The process is asymptomatic in the early stage of the disease, and hence screening programs are anticipatory [2]. The pathophysiology of DR is secondary to the chronic hyperglycemia, inducing endothelial injury in the retinal capillaries and thickening of basement membrane, loss of pericytes, micro aneurysm development, and disruption of the blood-retinal barrier [3].

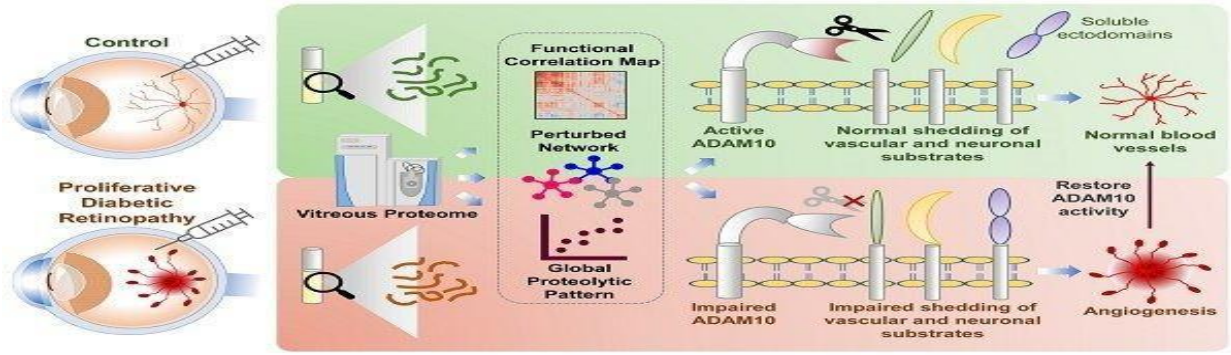

This cascade leads to ischemia, neovascularization, and fibro vascular growth and retinal detachment in advanced stages [4]. DR is typically divided into NPDR and PDR. NPDR represents the earlier onset, which is characterized by micro aneurysms, dot and blot hemorrhages, and cotton wool spots [5]. PDR is more serious and consists of pathological neovascularization, vitreous hemorrhage, and tractional retinal detachment, which results in sudden and irreversible visual impairment [6]. One of the rare but dangerous ones is diabetic macular edema (DME), which may occur at any phase of retinopathy. DME is enhanced vascular permeability with resultant fluid accumulation in the macula the portion of the retina devoted to central vision and is a major cause of visual disability in diabetics [7]. Early diagnosis is of utmost significance. Out of blindness caused by DR, statistics estimate that 90% may be avoided through early treatment and screening [8]. Screening may vary from dilated fundus examination to digital fundus camera and tele ophthalmology-based screening.

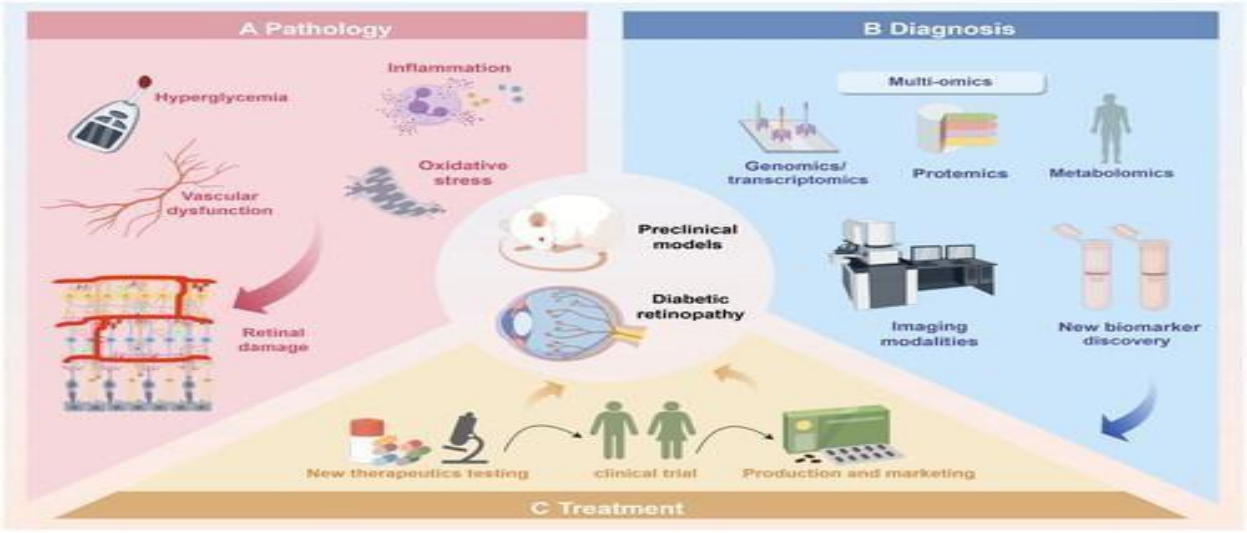

Telemedicine integration has been particularly seen to be useful in poor-resource and rural areas where there are no readily available ophthalmologists [9]. Treatment modalities are based on the course and severity of the disease. Panretinal photocoagulation (PRP) has remained the mainstay of treatment of PDR for decades [10]. Anti-vascular endothelial growth factor (anti-VEGF) drugs have altered treatment of DME and PDR with a dramatic makeover of visual outcomes [11]. In the more advanced forms of nonclearing vitreous hemorrhage or tractional retinal detachment, pars plana vitrectomy provides a surgical option to restore anatomical architecture and hinder further progression.

Methodology

We conducted a comprehensive literature study with the PubMed, Cochrane Library, and Scopus databases between 2010 and 2025 for published articles. Search terms included "diabetic retinopathy," "screening," "fundus photography," "laser photocoagulation," "anti-VEGF," and "tele ophthalmology." The ADA's primary clinical guidelines and AAO were studied to keep the article current with best evidence-based practice. Inclusion criteria were guideline recommendations, large cohort studies, metaanalyses, and randomized controlled trials in type 1 or 2 diabetic adults. Data abstracted were screening sensitivity and specificity, intervention efficacy impact, outcome for visual acuity, and disease progression rates. Results were synthesized using narrative synthesis and tabular display based on practicability of clinical use.

Results

Early detection and timely management of diabetic retinopathy are crucial for preventing vision loss. Various screening methods—ranging from traditional fundus examinations to advanced imaging—enable

accurate diagnosis. Treatment approaches such as laser therapy, anti-VEGF injections, and vitrectomy significantly reduce visual morbidity and preserve sight when appropriately indicated.

Table 1. Comparative Performance of Screening Modalities for Diabetic Retinopathy

Screening Method	Sensitivity (%)	Specificity (%)	Advantages	Limitations
Dilated fundus examination	85–90	85–90	Rapid access, relatively low cost	Requires trained staff, subjective variation
Fundus photography	80–88	84–90	Permanent documentation, allows follow-up	Equipment cost, image quality varies
Optical coherence tomography (OCT)	90–95	90–95	Detects macular edema, high-resolution imaging	High cost, limited rural availability
Teleophthalmology	85–90	80–88	Expands coverage to underserved populations	Internet-dependent infrastructure

Table 2. Current Therapeutic Approaches to Diabetic Retinopathy

Treatment Modality	Indication	Efficacy	Advantages	Limitations
Treatment Modality	**Indication**	**Efficacy**	**Advantages**	**Limitations**
Panretinal photocoagulation (PRP)	Proliferative diabetic retinopathy (PDR)	Reduces risk of severe visual loss by 50–60%	Proven long-term efficacy	Possible peripheral visual field loss
Focal/Grid laser	Clinically significant diabetic macular edema (DME)	Stabilizes visual acuity in most patients	Useful adjunct to anti-VEGF therapy	Less vision gain than anti-VEGF
Anti-VEGF injections	DME and PDR	Visual gain in 30–40% of patients	Effective, minimally invasive	Requires repeated injections, costly

Vitrectomy	Non-clearing vitreous hemorrhage, tractional retinal detachment	Restores anatomy, improves vision	Effective for advanced disease	Invasive, requires surgical expertise

Discussion

Diabetic retinopathy management is a multi-modal process that involves early diagnosis, timely intervention, and systemic disease control [12]. Prevention is screen-driven. Dilated fundus examination is cost-effective and viable based on the availability of specialists. Digital fundus photography has the added advantage of objective records and is also being used extensively in tele ophthalmology programs, which have been found to be extremely useful for coverage extension in the underserved areas [13]. Therapeutically, PRP remains a mainstay for proliferative disease with a 50–60% reduction in severe visual impairment [14]. Side effects like peripheral field limitation do require patient-specific decisionmaking. Anti-VEGF therapy, Ranibizumab, aflibercept, and bevacizumab have revolutionized the prognosis in DME and PDR with better visual outcomes than laser therapy alone [15]. Issues still remain, including the need for injections that must be repeated and cost considerations, especially in low-resource economies. Vitrectomy is warranted in late presentations, including non-clearing vitreous hemorrhage or tractional retinal detachment [16]. Preoperative anti-VEGF treatment can improve surgical results through intraoperative hemorrhage reduction and postoperative complications. In spite of these developments, real-life clinical usage is suboptimal. The most important challenges include poor follow-up, late presentation, and low-coverage screening [17]. Early diagnosis can be improved with the implementation of DR screening as an ongoing diabetes intervention, education of non-ophthalmic health workers, and computerized screening with AI-based technology [18]. Future therapeutic interventions include sustained-release anti-VEGF devices, neuroprotection agents, and gene therapy for early vascular alterations.

Conclusion

Early identification and treatment diabetic retinopathy is a preventable reason for blindness. Systematic approach to routine screening, correct diagnosis, and evidence-based treatment—aimed at disease stage—can decrease blindness rates to a high extent. The additional application of tele ophthalmology, hightechnology imaging, and new pharmacologic agent’s increases access and efficacy. Shared care by diabetologists, ophthalmologists, and general practitioners with imminent patient education will be critical to maintain vision and enhance quality of life in diabetics.

References

1. Tripathi, A., Gaur, S., Agarwal, R., Singh, N., Singh, A., Parveen, S., ... & Rima, N. (2025). Disorganization of retinal inner layers as an optical coherence tomography biomarker in diabetic retinopathy: A study. *Indian Journal of Ophthalmology*, *73*(9), 1245-1250.
2. Omar, A., Williams, R. G., Whelan, J., Noble, J., Brent, M. H., Giunta, M., ... & Lhor, M. (2024). Diabetic disease of the eye in Canada: consensus statements from a retina specialist working group. *Ophthalmology and Therapy*, *13*(5), 1071-1102.
3. Rahat, S. R. U. I., RAHMAN, M. H., Arafat, Y., Rahaman, M., Hasan, M. M., & Al Amin, M. (2025). Advancing diabetic retinopathy detection with AI and deep learning: Opportunities, limitations, and clinical barriers. *British journal of nursing studies*, *5*(2), 01-13.
4. Rák, T., Kovács-Valasek, A., Pöstyéni, E., Gábriel, R., & Csutak, A. (2025). Low Vision Rehabilitation and Eye Exercises: A Comprehensive Guide to Tertiary Prevention of Diabetic Retinopathy. *Life*, *15*(6), 857.
5. Baiju, B. V., Jain, D., Mehta, D. A., Thakur, S., & Jha, A. R. (2024, October). Predicting Diabetic Retinopathy with Machine Learning: Disentangling the Diabetes-Ocular Health Complex. In *2024 International Conference on Intelligent Systems and Advanced Applications (ICISAA)* (pp. 1-5). IEEE.
6. Wang, M. H., Xing, L., Pan, Y., Gu, F., Fang, J., Yu, X., ... & Liu, W. (2024). AI-based Advanced approaches and dry eye disease detection based on multi-source evidence: Cases, applications, issues, and future directions. *Big Data Mining and Analytics*, *7*(2), 445-484.
7. Hodges, B., Shahid, M. M., Qin, H., Omoruyi, F. O., Lyngdoh, J., Patel, D., & Allison, K. (2024). Evaluating the Incidence of Glaucoma, Age-Related Macular Degeneration, and Diabetic Retinopathy in Western New York and Assessing the Feasibility of Utilizing Optical Coherence Tomography and Artificial Intelligence for the Timely Identification of these Ocular Diseases. *J. Community Med. Public Health*, *8*, 453.
8. Šulak, M., Jevnikar, K., Drnovšek, F., Vrhovec, L., Urbančič, M., Potrč, M., ... & Petrovič, M. G. (2025). A stepwise implementation of the Slovenian National Diabetic Retinopathy Screening Program–evaluation of the first 4.5 years. *European Journal of Ophthalmology*, *35*(2), 660-668.
9. Julius, A., Malakondaiah, S., Subbarayalu, R., & Pothireddy, R. B. (2025). Role of Preoperative and Postoperative Intravitreal Anti-VEGF Agents in Managing Diabetic Macular Edema and Diabetic Retinopathy. *SN Comprehensive Clinical Medicine*, *7*(1), 175.

10. Melo, G. B., Malerbi, F. K., de Medeiros, J. N., & Grauslund, J. (2024). A comprehensive strategy of diabetic retinopathy screening in a public health system: identifying and overcoming obstacles for implementation. *Diabetes Epidemiology and Management*, *13*, 100192.
11. Rosenfeld, R. M., Grega, M. L., Karlsen, M. C., Abu Dabrh, A. M., Aurora, R. N., Bonnet, J. P., ... & Gulati, M. (2025). Lifestyle interventions for treatment and remission of type 2 diabetes and prediabetes in adults: a clinical practice guideline from the American College of Lifestyle Medicine. *American Journal of Lifestyle Medicine*, *19*(2_suppl), 10S-131S.
12. Radke, N. V., Ruamviboonsuk, P., Steel, D. H., Tian, T., Hunyor, A. P., Tsai, A. S., ... & Lam, D. S. (2025). Controversies, consensuses, and guidelines on macular hole surgery by the Asia– Pacific Vitreo-retina Society (APVRS) and the Asia–Pacific Academy of Professors in Ophthalmology (AAPPO). *Eye and Vision*, *12*(1), 30.
13. Alomari, O., Mokresh, M. E., Hamam, M., Teker, A. U., Caliskan, C. S., Sadigova, S., ... & Filinte, G. (2025). Combined Stromal Vascular Fraction and Fractional CO2 Laser Therapy for Hypertrophic Scar Treatment: A Systematic Study and Meta-Analysis. *Aesthetic Plastic Surgery*, *49*(3), 885-896.
14. Karabeg, M., Petrovski, G., Holen, K., Steffensen Sauesund, E., Fosmark, D. S., Russell, G., ... & Petrovski, B. E. (2025). Comparison of Validity and Reliability of Manual Consensus Grading vs. Automated AI Grading for Diabetic Retinopathy Screening in Oslo, Norway: A Cross-Sectional Pilot Study. *Journal of clinical medicine*, *14*(13), 4810.
15. Carrillo-Larco, R. M., Bravo-Rocca, G., Castillo-Cara, M., Xu, X., & Bernabe-Ortiz, A. (2024). A multimodal approach using fundus images and text meta-data in a machine learning classifier with embeddings to predict years with self-reported diabetes–An exploratory analysis. *Primary care diabetes*, *18*(3), 327-332.
16. Santos, L. F., Sánchez-Tena, M. Á., Alvarez-Peregrina, C., Sánchez-González, J. M., & Martinez-Perez, C. (2025). The Role of Artificial Intelligence in Optometric Diagnostics and Research: Deep Learning and Time-Series Forecasting Applications. *Technologies*, *13*(2), 77.
17. Lockhart, C. M., Barakat, M. R., Dunn, J. D., Richardson, T., Bratcher, T., Greene, E., ... & Wigginton, J. (2025). Transforming retinal disease management through diabetes care: AMCP Market Insights: Chief Medical and Pharmacy Officers Summit. *Journal of Managed Care & Specialty Pharmacy*, *31*(4-a Suppl), S1-S11.
18. Fickweiler, W., Sampani, K., Markel, D. S., Levine, S. R., Sun, J. K., & Gardner, T. W. (2025).

Advancing Toward a World Without Vision Loss From Diabetes: Insights From The Mary Tyler Moore Vision Initiative Symposium 2024 on Curing Vision Loss From Diabetes. *Translational Vision Science & Technology*, *14*(5), 12-12.